

The Central African Journal of Medicine

Volume 2

JANUARY, 1956

Number 1

Ileo-Cystoplasty in Chronic Bilharzial Cystitis

BY

R. M. HONEY,

M.B.CH.B. (Edin.), F.R.C.S. (Edin.), M.R.C.O.G.,
Consulting Surgeon, Salisbury General Hospital

AND

M. GELFAND, O.B.E., M.D., F.R.C.P.,

Consulting Physician, Salisbury General Hospital.

During the past ten years in which the authors have been collaborating on the investigation of the late results of urinary schistosomiasis, it early became apparent to one of us¹ that "hydronephrosis may occur in the absence of stricture of the ureter and in the presence of dilatation alone." The causes of this dilatation appear to be numerous, and were briefly discussed in their case reports in 1953.²

The first suggestions were made in 1948, when Gelfand had found during *post-mortem* investigations on this subject that the dilated portion of the ureter was that part in which the muscle had been most heavily destroyed by deposits of ova, with the resulting irritation, oedema and later fibrosis. He³ suggested that this destruction of the muscle interfered with its function to contract, and this still seems to be the cause of ureterectasis in many cases. The damaged wall not only lacks the power of onward propulsion of urine, but its tone is interfered with and this allows the normal intra-ureteric pressure to bring about dilatation of the diseased segment. In the later stages the massive deposition of fibrous tissue between the muscle bundles and the resultant avascularity causes pressure atrophy of the individual muscle cells, and the involved portion of the ureter is transformed into a dilated fixed fibrous tube. This diseased, dilated segment is usually the lower third or, as Camp-

bell Begg⁴ calls it, the lower spindle. The healthy ureter above this is usually of normal calibre and able to force the urine through the atonic lower third and into the bladder, with no obvious loss of efficiency.

If the whole length of the ureteric wall is the site of the deposition of ova in any number, the whole ureter dilates (Gelfand,³ Sayegh⁵). The muscle in the renal pelvis in such cases is at times not sufficiently powerful to force urine through the whole length of this damaged inert tube with normal efficiency, and the secretory pressure causes dilatation of the pelvis and calyces above this adynamic obstruction.

In the treatment of these patients who have dilated ureters, in the absence of stenosis and in the presence of bladders of normal capacity, little can be done apart from controlling the secondary infection which is a common complication. In the absence of infection the prognosis seems good.

On further investigation of this group of patients, however, it became obvious to us that there were quite a number of Africans in whom the dilatation was associated with a bladder of decreased capacity. Their clinical capacity to hold urine varies from 60 c.c. upwards. The bladder walls as seen at autopsy and operation are always grossly thickened and fibrous, and on histological examination show little muscle tissue, the whole thickness of the wall being composed of a mass of fibrous tissue in which are numerous bilharzial tubercles and eosinophil cells. Kirkaldy Willis⁶ mentioned briefly that one of the sequelae of bilharziasis is "hypertrophy of the bladder musculature which leads to hydronephrosis and the usual renal changes, but renal failure would seem to be much delayed." It is possible he was referring to this type of case. Sayegh⁵ also mentions the small contracted bladder and the associated distressing urgency, for which he recommended control of infection and pre-sacral neurectomy. He did

not state clearly that it was the small bladder which was responsible for the renal failure, but suggested that the hydronephrosis was due to accompanying ureteric stenosis.

Many of these bladders are practically incapable of expansion, and the actual capacity of the bladder is in the region of 10 c.c.

The intravesical pressure of these contracted infected bladders rises rapidly. If the internal sphincter does not open as soon as the small rigid cavity is filled, the remainder of the urine excreted must be accommodated in the ureters, pelves and calyces. This increasing pressure in the ureters, which must rise up to the secreting pressure of the urine, causes dilatation of the whole ureter, including the intramural portion, as well as the pelves and calyces. The dilated intramural portion is seen during cystoscopy as a gaping hole, and on cystogram evidence of its loss of valvular action is seen when dye placed in the bladder at once ascends and fills both the ureters and calyces. It should also be noted that in these patients it is the normal as well as the diseased segments of the ureter which dilate.

The prolonged back pressure eventually brings about pressure destruction of renal substance and the associated disturbance in renal function and eventually uraemia.

The problem of these bladders is very similar to that in burnt-out tuberculosis, in which the renal lesion is healed and the bladder lesion inactive, but with a fibrosed bladder wall and a greatly reduced capacity.

It was this similarity with its pathology of upper urinary tract destruction which impressed itself on us.

Following Cibert's article in 1953,⁷ we determined to try ileocystoplasty as the most rational form of therapy. We did not think that urinary diversion into the colon would give a good result in the presence of such gross ureteric dilatation, and diversion into an isolated ileal loop is not welcomed by the African, who has no means of obtaining frequent ileostomy bags or supplies of cement once he returns to his distant primitive home in the African bush.

The first African to give permission for this operation was admitted on 30th May, 1955.

Case Report.—Case No. 6265/1955, Salisbury African Hospital.

Jim is an African male, aged about 18 years. He complained that for some weeks before admission he had been unable to "hold" his urine for more than 10 to 30 minutes, and that he passed a very small quantity on each occasion. He also complained of pain in the left flank.

He was a thin and ill-looking youth, who appeared to have been ailing a longer time than he admitted.

Both kidneys were palpable, and on bimanual examination the bladder was palpable as a solid mass in the pelvis—the size and shape of a non-gravid uterus. The urine contained albumen, red cells, ova of *S. haematobium* and pus cells.

The blood pressure was 100/70 and his haemoglobin was 121 per cent.

Total leucocyte count was 12,000 per c.c.m., with a differential count of 61 per cent. neutrophils, lymphocytes 28 per cent., monocytes 6 per cent., and eosinophiles 5 per cent. The blood urea was 166 mg. on admission, and when repeated a week later was 60 mg. An intravenous pyelogram showed marked dilatation of the calyces on the left and no function on the right side.

A line typical of calcification due to bilharziasis was seen in the region of the bladder. The patient was then referred to Mr. Honey as a case which might be suitable for bladder enlargement by ileocystoplasty.

On 21st June, 1955, cystoscopy was carried out under spinal anaesthesia (Dr. J. D. Burrows).

A 24 F. cystoscope was admitted and 60 c.c. slightly turbid urine withdrawn; 60 c.c. sterile water was run in by gravity, from a height of 20 inches above the bladder, after which the inflow ceased. We judged the bladder capacity to be 60 c.c. The walls were pale and granular due to extensive submucous deposits of calcified ova and fibrous tissue—usually described as "bilharzial sand." The trigone was elongated antero-posteriorly and narrowed, with the ureteric orifices lying far back and close together. Both were widely patent of the golf-hole type. The walls seemed close together and the cavity no larger than that of a 10 c.c. syringe. Introduction of ureteric bougies was difficult owing to the small size of the bladder and its unyielding walls. Eventually a No. 9 Charrier bougie was passed up each ureter demonstrating the absence of stenosis.

A cystogram was then carried out by injecting 60 c.c. of Diadone into the bladder through the cystoscope, using a 20 c.c. syringe attached to the water inflow tap. During injection no great pressure was exerted on the plunger.

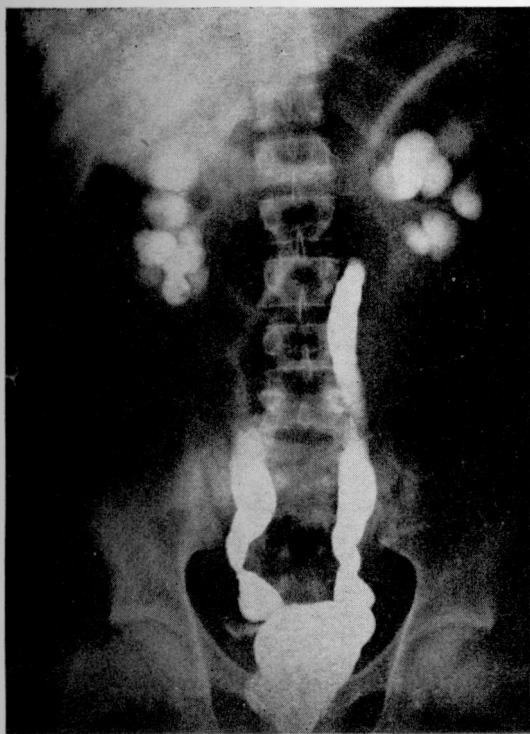


Fig. 1—Cystogram after injection of 60 c.c. Diodone.

The subsequent cystogram (Fig. 1) shows that most of the supposed 60 c.c. bladder capacity is in fact the combined capacity of the bladder, ureters and renal calyces which have been thrown into one continuous cavity with complete loss of the uretero vesical valve. There is gross dilatation of both ureters without stenosis, though at a point one inch above the uretero-vesical junction on the right there is some fibrosis preventing gross dilatation at this point and showing as a relative narrowing. The renal calyces are grossly dilated on each side. The pelves are not outlined. The vesicles and vasa are also filled, suggesting that the fluid was injected too rapidly.

As the pathology which was endangering his life was the small rigid bladder of decreased capacity, it was decided as a preliminary measure to drain the bladder.

After ten days' drainage, operation was carried out under general anaesthetic (Mr. Honey and Mr. Shepherd Wilson) to increase the bladder capacity by ileo-cystoplasty. The ileal loop was prepared as described in detail by Pyrah.⁸ The isolated loop was brought anterior to the re-united ileum. It was 12 inches long. Both its ends were closed and an opening one inch long made in its anti-mesenteric border about the middle of its length.

The bladder was of the size and consistence of a non-gravid uterus. The fundus was removed and sent for examination. Dr. Douglas H. Ross's report is:—

Histology No. 527/55

Material consists of a number of grossly thickened and fibrosed portions of bladder wall, the largest of which indicates a wall thickness of up to about 2 cm.

Sections show throughout the thickness of the wall innumerable deposits of bilharzial ova exciting marked focal reaction from purely cellular follicular type to well-developed fibrotic follicles, with associated eosinophilic response. There is diffuse fibrous replacement of the musculature which is represented solely by occasional groups of muscle bundles. Mucosa as

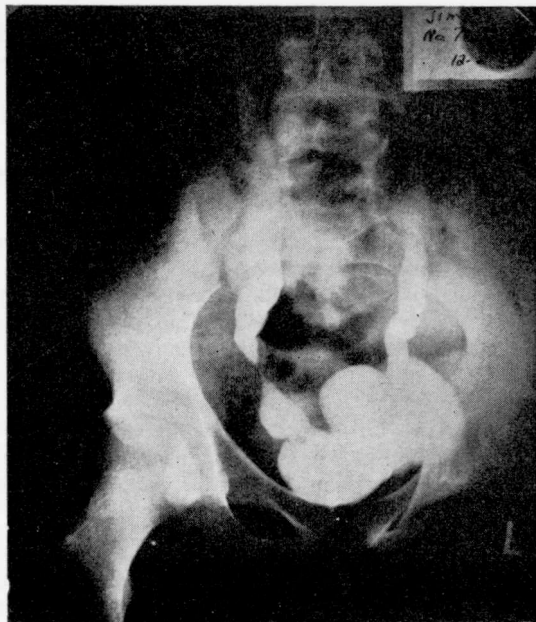


Fig. 2—Cystogram after the operation, showing the increased size of the "bladder."

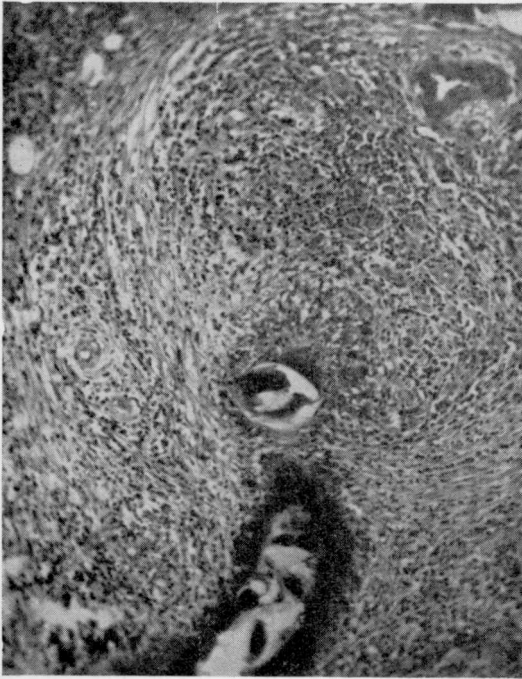


Fig. 3—Section of bladder wall stained by haematoxylin eosin to show acute cellular reaction with very early peripheral fibrosis. The dark crescentic area represents an acute necrotising reaction around a collection of ova.

such is not identified and is apparently debased and represented by fibrotic granulation tissue.

We are also indebted to Dr. Ross for photomicrographs Fig. 2 and Fig. 3.

The bladder cavity admitted a thumb with difficulty.

The ileal loop was anastomosed to the open bladder. No careful mucosa to mucosa anastomosis was possible, as all sutures cut out readily from the friable bladder. The junction was accomplished by six simple through and through No. 00 catgut sutures. The peritoneum was closed, leaving the anastomosis extraperitoneal. A drain was left down to the anastomosis. A urethral catheter was inserted having a terminal eye in the ileal loop and a lateral eye in the bladder cavity.

Post-operative progress was satisfactory. Urine drained slightly from the suprapubic drain for ten days. The catheter tended to become blocked with mucus, but patency was maintained by syringing. It was removed after 14 days.

Page Four

His condition was assessed on the 15th August (seven weeks post-operatively) by Mr. Shepherd Wilson, to whom we are indebted for this description and the cystogram (Fig. 4).

Dribbling incontinence had ceased. He could hold his urine for three hours. On passing urine at the end of three hours, the amount

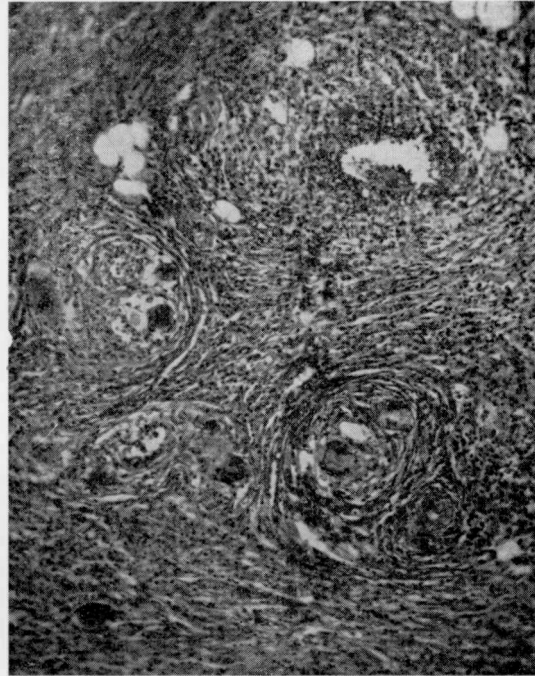


Fig. 4—Another area of bladder wall stained to emphasise early fibrosis and some follicles are seen in a more advanced stage of development.

passed was 190 c.c. He was observed while passing urine, and the act seemed quite normal. The stream appeared of normal force, commenced and terminated normally.

A cystogram was carried out by running in 200 c.c. of dye by gravity. The immediate picture did not show the ureters filled with dye, but after micturition the dye ascended the ureters as before (Fig. 4).

From the early results of this operation it appears that ileo-cystoplasty is a worthwhile procedure in this type of case. His distressing symptoms have been relieved, his blood urea remains within normal limits and he has returned to his home. It is unfortunate that Africans seldom return on request for long-term post-operative evaluation.

SUMMARY

Ureterectasis as a complication of schistosomiasis and in the absence of stenosis is discussed.

It occurs in two forms:

- (a) In patients with bladders of normal capacity.
- (b) In patients with chronic bilharzial interstitial cystitis in whom the bladder capacity is reduced;

and a case is reported in whom ileo-cystoplasty was used with satisfactory early result.

REFERENCES

1. GELFAND, M. (1948). *Brit.Med.J.*, 26th June.
2. GELFAND, M. & HONEY, R. M. (1953). *S.Afr.Med.J.*, 27, 327.
3. GELFAND, M. *Schistosomiasis in South and Central Africa*. Capetown Post Graduate Press and Juta and Co. Ltd.
4. CAMPBELL BEGG, R. (1946). *Brit.J.Urol.*, xviii, 176.
5. SAYECH, F. S. (1950). *J.Urol.*, 63, 360.
6. KIRKALDY WILLIS, W. A. (1946). *Brit.J.Surg.*, xxxiv, 189.
7. CIBERT, J. (1953). *Brit.J.Urol.*, xxv, 99.
8. PYRAH, L. N. (1955). *Brit.J.Surg.*, xlii, 337.

Acknowledgment

We wish to thank the Secretary for Health for his permission to publish this paper.

